

## 17. THE REPRODUCTIVE SYSTEM

The function of the reproductive system is to ensure survival of the species. We distinguish male and female reproductive systems.

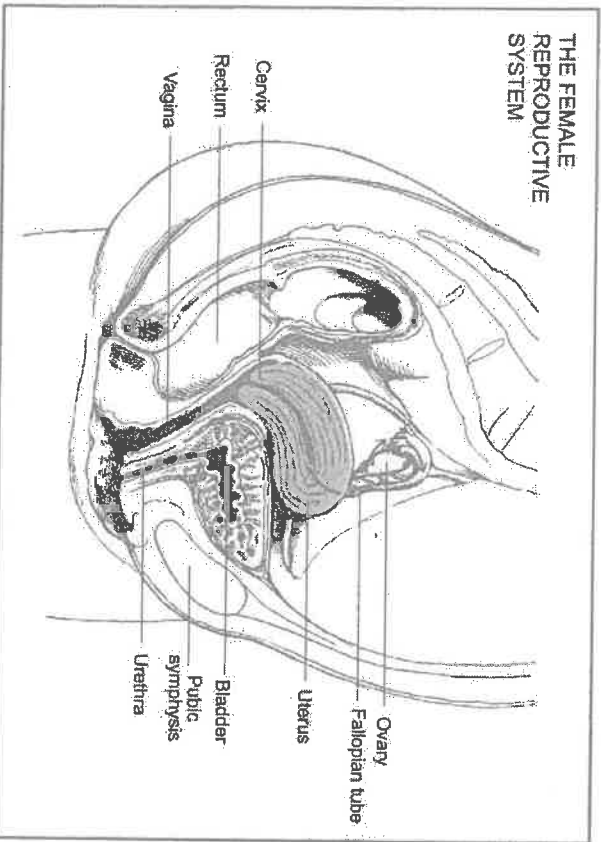
The specific role of the female is to provide an optimal environment for the development of the foetus. The female reproductive system is divided into the external and the internal genitals.

The **external genitals** include the following structures: the mons Veneris (the labia majora, labia minora, clitoris, vestibule, vulvovaginal gland and the hymen).

**Internal genitals**, e.g. two ovaries, two Fallopian tubes, uterus and vagina are situated in the body pelvis which gives them excellent protection from accidental injuries and are located in an intimate contact with the bladder and the rectum.

There are also several **accessory structures** such as the perineum, the pelvic floor, the pelvic connective tissue, the pelvic peritoneum and the breasts.

### The Female Reproductive System



The ovaries are oval, about 4 cm long organs, but their size may vary in different people and even in the same individual the two ovaries may differ considerably. They are situated one on each side of the uterus near the pelvic wall and close to the outer end of the Fallopian tubes. In structure, the adult ovary is simply a collection of ova, or microscopic eggs, supported and held together by tissue, which forms the framework. Each ovum contains a sac called the **graafian follicle**, and a section of an ovary shows graafian follicles in various stages of development. Thousands of young follicles lie near the surface and as they mature, they increase in size and approach the surface.

The hormone oestrogen is secreted by the developing follicle and under its influence the endometrium begins to regenerate and thicken. When the ripe follicle bursts, the liberated ovum is discharged and passes into the Fallopian tube. This process is called **ovulation**. Many eggs develop, but only one may ovulate, the others die.

After ovulation a small yellow body called the **corpus luteum** forms in the ovary, where the ovum was held and secretes progesterone, which prepares the endometrium for the embedding of a fertilized ovum.

Fertilization can occur during the 4 – 5 days needed for the ovum to travel the length of the tube if sperms are present. If the ovum is not fertilized, the corpus luteum degenerates and the endometrium is expelled, which leads to **menstruation or menses**.

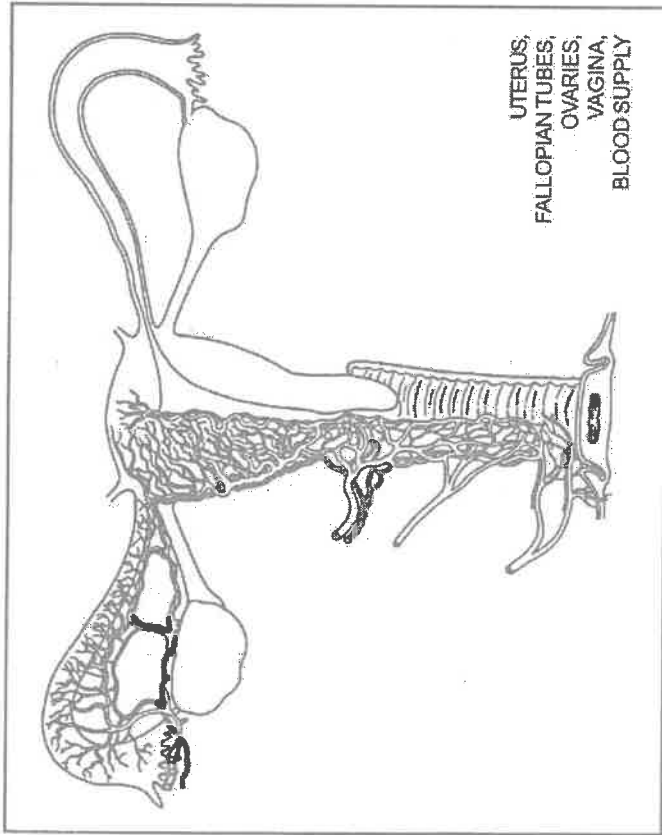
The endometrium is the mucous membrane of the body of the uterus and after fertilization it gives nourishment to the developing embryo.

The **Fallopian tubes** are two small muscular tubes; one on each side of the uterus and their function is to convey ova from the corresponding ovary to the uterus, which is possible due to peristaltic contractions of the tube toward the uterus.

The **uterus** is a strong, muscular organ, located in the pelvis between the bladder and the rectum. It is freely movable, especially the upper part and may be pushed backward by a full bladder or forward by a full rectum. The uterus receives the fertilized ovum, sustains and protects it through the various stages of growth and expels the developed child at term. It is capable of enormous enlargement during pregnancy and returns to nearly its former size (which is 7.5 cm) afterwards.

The **vagina** is a musculomembranous canal extending from the vulva to the neck of the uterus called **cervix**, to which it is attached. It is the female organ of sexual intercourse and also serves as a passage for the foetus

during labour. Its size and shape are variable and it is also capable of great distention, as is seen when the child passes through it. Normally, the anterior and posterior vaginal walls lie in contact and on a cross-section of the cavity; it has the shape of the letter H. The anterior wall is in contact with the urethra and the base of the bladder. The cyclic changes of the vaginal epithelium are under the control of ovarian hormones.



Disorders of the reproductive system are especially stressful. Many of them can involve the possibility of a large number of tumours (benign fibromyoma or cancers).

Disorders of menstruation are quite common. It may be:

Dysmenorrhoea – which is a painful menses,

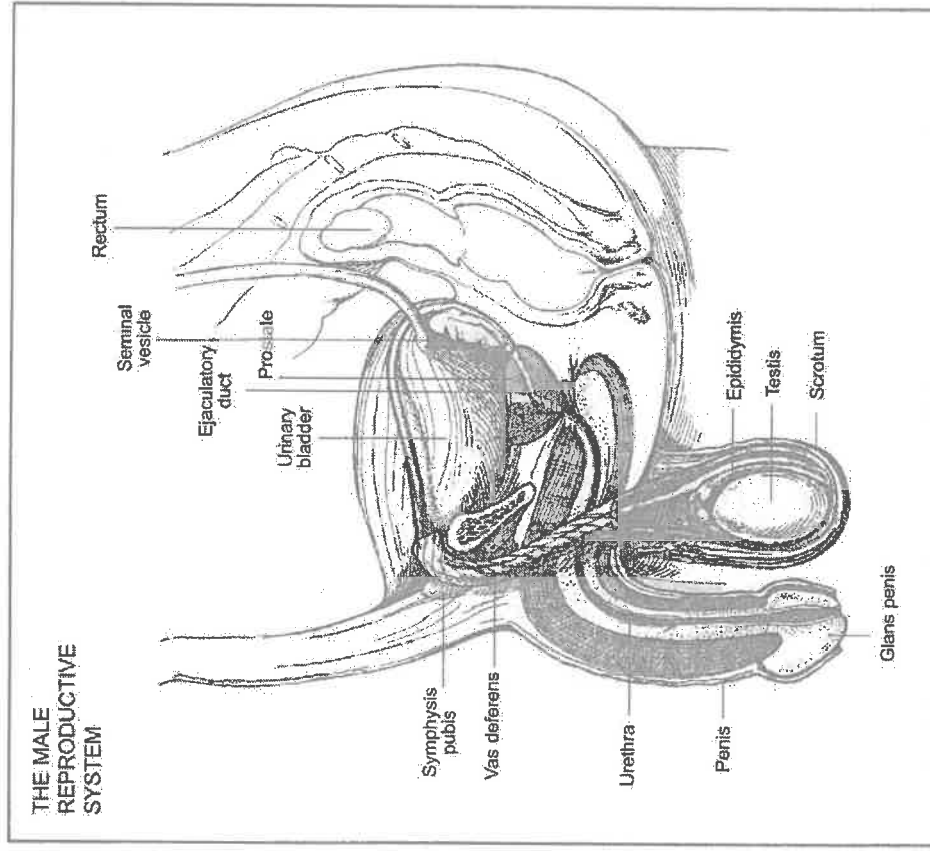
Menorrhagia – a heavy bleeding that lasts longer than 5 to 7 days,

Amenorrhoea – the lack of menses, caused by the emotional stress or by a disease,

Metrorrhagia – a bleeding that occurs other than during regular menses and is an abnormal condition, which may be caused by a tumour.

The other disorders of the female reproductive organs are, for instance:  
 Vulvitis – inflammation of the vulva,  
 Vaginitis – inflammation of the vagina,  
 Cervicitis – inflammation of the cervix,  
 Mastitis – inflammation of the breast tissue; ovarian cysts and tumours, breast cancers or some other sexually transmitted diseases.

### The Male Reproductive System



It consists of two testes, four types of excretory ducts, a penis and three different accessory glands.

The two testes are located in a double sac called the scrotum and have two functions: production of sperm (spermatogenesis) and production of testosterone, the male hormone.

The excretory ducts are the ducts that carry sperm and semen. They are of four types: the epididymis, the vas deferens, the ejaculatory duct and the urethra.

The penis is composed of three layers of erectile tissue, with spaces that fill with blood to produce erection during sexual arousal. In an erection, it becomes enlarged and rigid, which facilitates coitus.

The accessory glands of the male reproductive system are the seminal vesicles, prostate gland and two pea-sized Cowper's glands. They secrete an alkaline substance that comprises the fluid portion of semen.

Disorders of the male reproductive organs have serious psychological and physical effects. Sexual function may be affected by the patient's worry about the possibility of impotence. There exist many congenital abnormalities that are relatively common and can be repaired surgically early in life, and also many painful inflammations of some organs. One of the serious disorders in elderly men is an enlargement of the prostate and approximately 25 % of these patients develop cancer of the prostate.

There are also several sexually transmitted diseases, which can affect both men and women, such as gonorrhoea, syphilis, herpes and AIDS. AIDS (immunodeficiency syndrome) is a relative new disease. It was first recognized in the U.S.A. in 1981, but the virus, known as the human immunodeficiency virus (HIV), which is responsible for the disease, was not isolated until 1983.

The transmission of the HIV virus is through blood or blood products. The common methods of the transmission are:

- Through sexual activity, particularly anal intercourse.
- Through the sharing of infected needles by those injecting drugs.
- Through the accidental transfusion of patients with infected blood.
- By congenital infection, which means the transmission of the virus from an infected mother to an unborn baby.

The course of the disease involves four stages. Firstly, when the person becomes infected, he may feel generally unwell for a few days, as if he has a very bad cold. Afterwards, this disappears and he feels perfectly

healthy. It may continue for several years and this period is known as the asymptomatic stage. The third stage is called the persistent generalised lymphadenopathy (or PGL) when most of the patient's lymph nodes swell up, but he still does not feel ill. The fourth stage is AIDS itself, the patient suffers from unusual infections or tumours and his immune system is too weak to resist.

After a period lasting months or even a year, when the patient feels very ill, he dies.

There is no treatment for HIV infection (although in some patients a healthy life - style can extend their life for up to 20 years) and it is likely that everyone infected with HIV will get AIDS.

## VOCABULARY

abortion [ə'bo:ʃn]	potrat [pɔtɛr'ɦɔkɔkɔfɪ pɪvɔdɔ]
accessory [ə'sesəri]	přídavný
adhesion [əd'hɪʒn]	srůst
breast [breɪst]	prs
breast feeding [breɪst fi:dɪŋ]	kojení
burst [bɜ:st]	prasknout
cease [si:z]	zastavit, přestat
cervix [sɜ:'vɪks]	děložní hrdlo
cervicitis [sɜ:'vɪsɪtɪs]	zánět děložního hrdla
childbirth [ˈtʃaɪldbɜ:θ]	porod [pɔrɔd (ɦɔdɔvɛ)]
climacteric [klaɪmækt'etɪk]	přechod
clitoris [kli'tɪrɪs]	klitoris
contraception [kɒntrə'sepʃn]	antikoncepce
convey [kən'veɪ]	dopřavit, odeslat
delivery [dɪ'lɪ:ven]	porod
delivery room [ru:m]	porodní sál
endometrium [ɛndə'mɪ:triəm]	děložní sliznice
expectant mother [ɪks'pektənt mʌðə]	těhotná matka
fertility [fɛ:'tɪlɪtɪ]	plodnost
fertilization [fɛ:'tɪlaɪ'zeɪʃn]	opločnění
foetus [fɪ'tes]	plod
foetus distress [dɪ'stres]	ohrožení plodu
genital tract [dʒɛ'nɪtɪl trækt]	rodidla

<b>genitals external</b> [dʒenɪtɪz ɛk'ste:ml]	vnější rodidla
<b>genitals internal</b> [ɪn'te:ml]	vnitřní rodidla
<b>habitual abortion</b> [hə'bitʃuəl ə'bo:ʃn]	opakovaný potrat
<b>hymen</b> [haimən]	panenská blána
<b>infertility</b> [ɪnfə'tɪləti]	nepłodnost
<b>labia majora</b> [leɪbiə mə'dʒo:rə]	velké stydké pysky
<b>labia minora</b> [ləɪbɪə mɪ'nɔ:rə]	malé stydké pysky
<b>labour pains</b> [leɪbə peɪnz]	porodní bolesti
<b>liberate</b> [lɪbə'reɪt]	uvolňovat
<b>midwife</b> [mɪdwaɪf]	porodní asistentka
<b>menstruate</b> [men'stru:et]	menstruovat
<b>(= to have periods)</b> [tə hæv 'piəriəds]	mít měsíčky
<b>miscarriage</b> [mɪs'kærɪdʒ]	spontánní potrat
<b>mons Veneris</b> [monz venərɪs]	hrbolek stydký
<b>nourish</b> [na:ʃ]	vyživovat
<b>obstetrics</b> [ɒbs'tetɪks]	porodnictví
<b>obstetrician</b> [ɒbstetɪʃn]	porodník
<b>ovum, pl. ova</b> [əʊvəm]	vejce
<b>pelvic floor</b> [pelvɪk flo:]	dno pánevní
<b>perineum</b> [perɪ'ni:əm]	hráz
<b>pregnancy</b> [pregnənsɪ]	těhotenství
<b>pubic hair</b> [pju:bɪk heə]	ochlupení ohanbí
<b>sac</b> [sæk]	váček
<b>surface</b> [sɜ:fɪs]	povrch
<b>sustain</b> [sə'steɪn]	utrpět
<b>testes</b> [testɪz]	varlata
<b>vas deferens</b> [vɑ:s defərəns]	chánmovod
<b>vestibule</b> [vestɪbjʊ:l]	vchod, předstín
<b>womb</b> [wʊ:m]	děloha (lídově)

### QUESTIONS AND EXERCISES

Answer:

1. What is the function of the reproductive system?
2. What are the external genitals?
3. Describe the internal genitals.
4. Describe the function of the ovaries.
5. Describe the ovulation process.

6. What is the corpus luteum?
7. Describe the uterus.
8. Describe the vagina.
9. What does the male reproductive system consist of?
10. Describe the function of various organs.
11. Talk about some disorders of the reproductive system.
12. Talk about some sexually transmitted diseases.
13. What do you know about AIDS?

Translate:

reprodukční soustava; zajistit přežití druhu; poskytuje optimální prostředí; vývoj plodu; přídavné orgány; hráz; dno pánevní; vaječníky; vejcovody; děloha a vagina; ochrana před poraněním; jeden na každé straně; vajíčka obsahují váček; různá stadia vývoje; leží blízko povrchu; jakmile uzrají, zvětší se; děložní sliznice se začíná obnovovat a tloustnout; zralý folikul praskne; uvolněné vajíčko je vypuzeno; žluté tělísko; uhnízdění oplodněného vajíčka; volně pohyblivý; schopen značného zvětšení; příčný řez dutiny; silné krváčení; vylučovací kanálek; varlata; nadvarle; vrozené vady; sexuálně přenosné nemoci; nakažený nemocí AIDS